

Case Report

Exfoliative dermatitis due to dermatophytosis

Risa Miliawati Nurul Hidayah¹, Andini Dwikenia Anjani¹, Lies Marlysa Ramali¹, Oki Suwarsa¹, Hendra Gunawan¹

¹ Department of Dermatology and Venereology, Faculty of Medicine, Universitas Padjadjaran - Hasan Sadikin General Hospital, West Java, Indonesia

Abstract

Exfoliative dermatitis (ED) or erythroderma is defined as diffuse erythema and scaling of the skin involving more than 90% of the total body skin surface, which can be caused by variety of systemic and cutaneous diseases, such as infection, including dermatophytosis. Dermatophytosis is a superficial fungal infection of keratinized tissue caused by dermatophytes. There are only few case reports of ED due to dermatophytosis in literature. A 39-year-old male present with history of diffuse erythematous macules and scales almost on entire body due to dermatophytosis was reported. The diagnosis of dermatophytosis was confirmed by direct microscopic examination, fungal culture, and histopathological examination. Patient was treated with 2% ketoconazole shampoo and two pulses of 1-week of 200 mg itraconazole twice a day for each month. Clinical improvement was showed on the 7th day of observation characterized by decreasing of erythematous macules and scales. Mycological and clinical improvements were obtained on the 29th day of observation. The etiology of ED should be determined in order to give an appropriate treatment.

Key words: dermatophytosis; dermatophyte; exfoliative dermatitis.

J Infect Dev Ctries 2021; 15(2):306-309. doi:10.3855/jidc.12218

(Received 15 November 2019 – Accepted 25 April 2020)

Copyright © 2021 Hidayah *et al.* This is an open-access article distributed under the Creative Commons Attribution License, which permits unrestricted use, distribution, and reproduction in any medium, provided the original work is properly cited.

Introduction

Exfoliative dermatitis (ED) is an inflammatory skin disorder characterized by erythema and scaling almost all over the body. This condition classically involves greater than 90% of the body surface [1]. Determining the etiology of ED can be a challenge because it can be caused by various cutaneous and systemic diseases. Dermatophytes infection is one of the less common cause of ED in adults [2].

Dermatophytosis is infection of skin, hair, and nails caused by a dermatophyte [3,4]. There are three genera of dermatophyte: *Epidermophyton*, *Microsporum*, and *Trichophyton* [3]. Dermatophytosis is the most common superficial fungal infection worldwide [5,6]. It involves about 3.6% of patients with skin disorders [6]. The disease is most found in tropical countries [4,5] and in areas with high humidity level [5]. The most common causes of dermatophytosis in Indonesia are *Trichophyton rubrum* (*T. rubrum*) and *T. mentagrophytes* [7]. The prevalence of ED caused by infection is about 4% [8]. The aim of this report was to demonstrate a rare case ED due to dermatophytosis.

Case Report

A 39-year-old male patient presented with diffuse erythematous macules and scales almost on entire body

surface. He had history of pruritic erythematous macules on both elbow and forearm for the last 10 years. Patient took oral corticosteroid by himself to reduce the itch. One year prior to consult, there were pruritic erythematous macules with scales and some papules on the edges of the lesions on his inguinal area, which spread to the abdominal area and limbs. There was history of treatment with topical antifungal and oral corticosteroid. The symptoms were reduced after taking the medications. One month prior to consult, the erythematous macules and scales extended to the scalp accompanied with hair loss and the scales on the body became thicker. One week prior to consult, the lesions spread onto face area and throughout the entire body surface. There were no fever, chills, or lymphadenopathy.

Physical examination showed moon face and central obesity. There were diffuse scaly erythematous macules over the body and some pustules on the abdomen (Figures 1A and 1C). Onychodyscoloration and onychodystrophy on his nail fingers and toes were also found. The results of direct microscopic examination with 10% potassium hydroxide (KOH) solution of scales, which were taken from the skin surface, revealed long branched septate hyphae. Direct microscopic examination with Gram staining of

pustular lesions was sterile. The result of histopathologic examination from scaly erythematous macules on buttock with Periodic acid-Schiff (PAS) revealed multiple hyphae on corneal layer (Figure 2). These findings were confirmed by fungal culture examination that revealed *T. rubrum*.

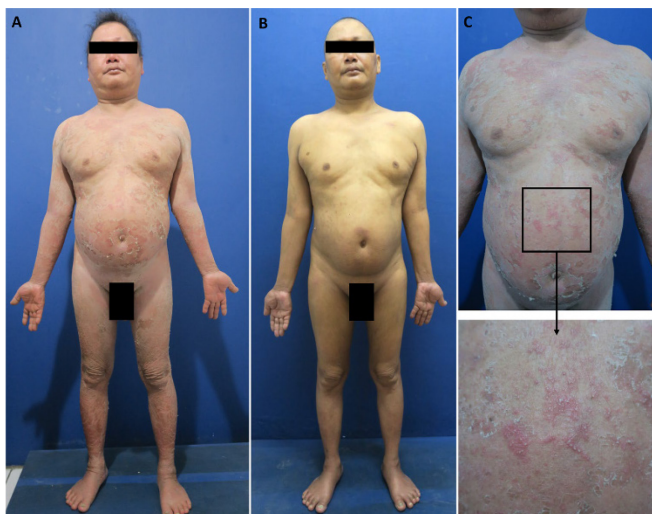The patient in this case received 2% ketoconazole shampoo that applied to affected and surrounding areas including pustules, three times a week for one month. As an adjunct to topical antifungal treatment, patient also received 10% urea lotion two times a day for one month. For systemic therapy, patient received two pulse of 1-week of 200 mg itraconazole twice a day for each month. Clinical improvement such as decreased of erythematous macules and scales was observed on the 7th day of observation. Significant mycological and clinical improvements were obtained on the 29th day of observation (Figures.1B), while fungal culture became negative on the 64th day of observation.

Discussion

ED is an intense generalized redness of the skin, first described by Von Hebra in 1868 [1]. The classic presentation of ED is erythematous patches that increase in size and coalesce into generalized red erythema. By definition, ED involves more than 90% of the patient's skin surface [2]. In this case, the patient presented with erythematous macules and scaling over the whole body.

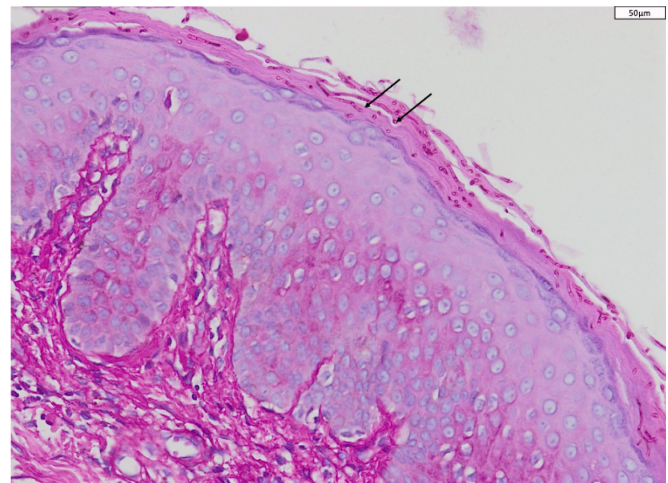
The recognition of ED is easy, but the diagnosis of the underlying cause is challenging. Determining the correct diagnosis require consideration of initial sites of

Figure 1. Clinical manifestation of ED.



(A). before treatment, (B). after treatment, (C). pustular lesions developed over abdomen.

Figure 2. Histopathological result.



Many fungal hyphae in the corneal layer and parakeratosis (arrows) (periodic acid Schiff, ×200).

involvement, additional clinical findings, histological features, and associated systemic abnormalities, as well as a complete medical history [2,9]. There are various cases of ED, but dermatophytosis may present as ED is rare [9]. ED can be caused by aggravation of a pre-existing skin disease. Common underlying of ED are dermatoses like psoriasis and atopic dermatitis [2]. Serarslan reported a patient who had widespread tinea infection on her trunk and face caused by *T. rubrum* after topical corticosteroid application, resembling psoriasis [10]. Namazi et al. reported a case of generalized pustular psoriasis-like dermatophytosis due to *T. rubrum* [11]. The differential diagnosis in this case report was pustular psoriasis. Several examinations to rule out psoriasis or any other casue of ED were carried out.

There are only few case reports of erythrodermic fungal infection in the literature. Two reported cases were due to *T. violaceum*. One case developed in patients with congenital ichthyosiform erythroderma. The other case occurred in patient receiving immunosuppressive therapy [9]. Extensive dermatophytosis is common in immunocompromised patient [12]. The use of corticosteroid as single or in combination with various antifungal creams gives rapid symptomatic relief but can lead to the spread of fungal infection [12]. In this case report, patient had received long-term oral corticosteroid for reducing the itching. This emphasize the fact that there has been inappropriate use of corticosteroids which led to a state of ED.

The distribution of dermatophytosis and its etiological vary, depending on geographical region,

warm and humid climate [13], socioeconomic status, lifestyle, and migration [14]. Apart from environmental conditions, poor personal hygiene along with poor illiteracy play major role in influencing the higher incidence of dermatophytosis [4]. Other predisposing factors that cause individuals to become infected and occur heavier and widespread infections are the underlying diseases, such as diabetes mellitus, lymphoma, immunocompromised conditions, Cushing's syndrome, old age [15], and immunosuppressive drug therapy [16]. Dermatophyte-induced ED is a rare entity that usually occurs in immunocompromised patient. However, it may occur without obvious underlying immunological abnormalities [9]. Predisposing factors in this patient were often sweating and long-term use of oral corticosteroid.

Dermatophyte-induced ED can be detected by direct microscopic examination with 10% KOH solution and confirmed by fungal culture and histopathological findings. Cultures are incubated at room temperature for at least four weeks before finalized as no growth [2]. *T. rubrum* is the most common causative agent of dermatophytosis. It has been describe in the literature that *T. rubrum* can cause chronic and generalized skin infection [15]. In ED due dermatophytosis, the histopathological features show neutrophils in the stratum corneum, sandwich sign (orthokeratosis or parakeratosis alternated in layers with basket-weave stratum corneum). Hyphae are seen within the parakeratotic and orthokeratotic areas. Fungal hyphae in the stratum corneum, visible with PAS stains [9,17]. In this case, we did the biopsy to rule out the other causes of ED, because getting culture results required quite a long time. Histopathological examination result of this case revealed parakeratosis and mild hyperkeratosis. In the dermis and reticular dermis papillae, there were infiltration of lymphocytes and neutrophils, and hyphae in the corneal layer was found on PAS staining. Direct microscopic examination in this patient showed long branched septate hyphae and fungal culture demonstrated the growth of *T. rubrum*.

Treatment strategies for ED should address the dermatologic disease as well as the underlying etiology and the systemic complication of ED [9]. In case of ED due to dermatophytosis, it could be treated with topical and systemic antifungal agents [7,9]. Dermatophytosis with inflamed lesions or hyperkeratosis, can be treated with pulse dose of 1-week oral itraconazole (200 mg twice daily for each month). In the case of hyperkeratosis, topical treatment with 10% urea lotion can be valued [7]. Comparative trial between

itraconazole with griseofulvin for *tinea corporis* or *tinea cruris* showed significantly better clinical and mycological outcome in favor of itraconazole after 2 weeks of therapy [15]. Patient in this case was treated with topical therapy of 2% ketoconazole shampoo three times a week and 10% urea lotion twice a day for one month, and two pulses of 1-week itraconazole. Clinical improvement was observed on the 7th day of observation as the scales became thin and erythematous macules became hyper pigmented. Direct microscopic examination showed no fungal elements after one month of first pulse itraconazole treatment (29th day of observation) and fungal culture became negative after one month of second pulse itraconazole treatment (64th day of observation). In this case report, itraconazole appeared to be effective in terms of clinical and mycological cure rates (both microscopy and culture).

Conclusions

Exfoliative dermatitis due to dermatophytosis is very rare. It can occur in patient on long-term use of oral corticosteroid. The etiology of ED should be determined in order to give an appropriate treatment.

Acknowledgements

Authors would like to thank all of the staff Dermatology and Venereology Department, Faculty of Medicine Universitas Padjadjaran - Hasan Sadikin General Hospital

References

- Okuduwa C, Lambert WC, Schwartz RA, Kubeyinje E, Etiokpah A, Sinha S, Chen W (2009) Erythroderma: a review of a potentially life-threatening dermatosis. *Indian J Dermatol* 54: 1-6.
- Grant-Kels JM, Fedeles F, Rothe MJ (2012) Exfoliative dermatitis. In Goldsmith LA, Katz SI, Gilchrist BA, Paller AS, Leffel DJ, Wolff K, editors. *Fitzpatrick's dermatology in general medicine*, 8th edition. New york: McGraw-Hill. 2277-2297.
- Lavanya M, Rao RB, Jayanthi S, Nagamani RA (2016) A clinical, epidemiological and therapeutic scenario of dermatophytosis in a tertiary care hospital in the State of Telangana, India. *Int J Res Med Sci* 9: 4005-4009.
- Vijaykumar R, Vijaymaran RS, Rangarjan S, Kindo AJ (2016) Incidence and prevalence of dermatophytosis in and around Chennai, Tamilnadu, India. *Int J Res Med Sci* 3: 695-700.
- Surendran KAK, Bhat RM, Boloor R, Nandakishore B, Sukumar D (2014) A clinical and mycological study of dermatophytic infections. *Indian J Dermatol* 59: 262-267.
- Qadim HH, Golphoroushan F, Azimi H, Goldust M (2013) Factors leading to dermatophytosis. *Ann parasitol* 59: 99-102.
- Adiguna SM (2013) Epidemiologi dermatomikosis superfisialis di Indonesia. In Bramono K, Suyoso S, Indriatmi W, Ramali LM, Widiaty S, Ervianti E, editors.

- Dermatomikosis superfisialis, 2nd edition. Jakarta: Badan Penerbit FKUI. 1-7.
8. Schieke SM, Garg A (2012) Superficial fungal infection. In Goldsmith LA, Katz SI, Gilchrist BA, Paller AS, Leffel DJ, Wolff K, editors. Fitzpatrick's dermatology in general medicine, 8th edition. New York: McGraw-Hill. 2277-2297.
 9. El-Daraouti MA (2013) An extremely rare cause of erythroderma. In El-Daraouti MA, editor. Challenging cases in dermatology. London: Springer. 371-378.
 10. Serarslan G (2007) Pustular psoriasis-like tinea incognito due to *Trichophyton rubrum*. *Mycoses* 50: 523-524.
 11. Feily A, Namazi MR, Seifmanesh H (2011) Generalized pustular psoriasis-like dermatophytosis due to *Trichophyton rubrum*. *Acta Dermatovenerol Croat* 19: 209-211.
 12. Naik SM, Kamoji SG, Nayak J (2016) The rising menace of steroid abuse cascading from tinea incognito to erythroderma. *JERDV* 2: 1-3.
 13. Havlickova B, Czaika V, Friedrich M (2008) Epidemiological trends in skin mycoses worldwide. *Mycoses* 4: 2-15.
 14. Ameen M (2010) Epidemiology of superficial fungal infections. *Clin Dermatol* 28: 197-201.
 15. Sahoo AK, Ahajan R (2016) Management of *tinea corporis*, *tinea cruris*, and *tinea pedis*: a comprehensive review. *Indian Dermatol Online J* 7: 77-86.
 16. Gloria M, Sousa T, Santana GB, Criado PR, Benard G (2015) Chronic widespread dermatophytosis due to *Trichophyton rubrum*: a syndrome associated with *Trichophyton*-specific functional defect of phagocytes. *Front Microbiol* 6: 801.
 17. Park YW, Kim DY, Yoon SY, Park GY, Park HS, Yoon HS, Cho S (2014) 'Clues' for the histological diagnosis of tinea: how reliable are they? *Ann Dermatol* 26: 286-288.

Corresponding author

Hendra Gunawan, MD, Ph.D

Department of Dermatology and Venereology, Faculty of Medicine

Universitas Padjadjaran - Hasan Sadikin General Hospital

Pasteur 38 Bandung, West Java 40161 Indonesia

Phone: +62222032426 ext. 3449

Fax: +62222032426

E-mail: h.gunawan2016@unpad.ac.id

Conflict of interests: No conflict of interests is declared.