

Case Report

Pulmonary nocardiosis presenting as fungal ball—a rare entity

Ragini Tilak,¹ D. Agarwal,² T.K. Lahiri,² Vijai Tilak.³

¹Department of Microbiology, Institute of Medical Sciences, Banaras Hindu University, Varanasi-221 005 India.

²Department of Cardiovascular and Thoracic Surgery, Institute of Medical Sciences, Banaras Hindu University, Varanasi-221 005 India.

³Department of Pathology, Institute of Medical Sciences, Banaras Hindu University, Varanasi-221 005, India.

Abstract

Pulmonary intracavitary infection caused by *Nocardia* is an opportunistic infection and is believed to be a rare entity. We describe a case report of a patient with culture positive *Nocardia asteroides* who presented with complaints of cough and expectoration with episodes of haemoptysis and dyspnoea. The diagnosis of nocardiosis was made by microscopic examination of the surgically resected portion of the lung and confirmed on culture.

Key Words: *Nocardia asteroides*, Opportunistic infection, Sabouraud's dextrose agar.

J Infect Developing Countries 2008; 2(2):143-145.

Received 29 October 2007 - Accepted 1 February 2008.

Copyright © 2007 Tilak *et al.* This is an open access article distributed under the Creative Commons Attribution License, which permits unrestricted use, distribution, and reproduction in any medium, provided the original work is properly cited.

Introduction

Nocardia produce opportunistic pulmonary disease known as nocardiosis in immunocompromised individuals, including those with acquired immunodeficiency syndrome (AIDS). Soil is known to be a natural habitat of *Nocardia*. It is therefore believed that man acquires infection by inhalation of the bacteria from environmental sources. Pulmonary fungal ball can be defined as a conglomeration within a lung cavity or ectatic bronchus or intertwined fungal hyphae matted together with fibrin, mucus and cellular debris [1]. Pulmonary intracavitary infection with *Nocardia asteroides* is rare, which prompted us to report this case.

Case Report

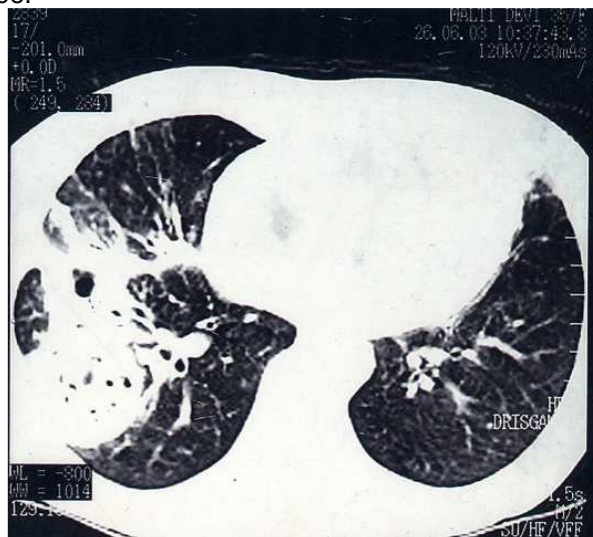
A 32-year-old female presented with cough and expectoration with episodes of haemoptysis for 2 years and grade II dyspnoea for 1 year. She had past history of epilepsy controlled with eptoin. She was taking antitubercular treatment (ATT) for seven months. With ATT, her fever had subsided and the amount of sputum had decreased, but haemoptysis had continued.

On general examination she was underweight with a body weight of only 34 kg. There was pallor; however, there was no jaundice, clubbing or

lymphadenopathy. Respiratory examination revealed diminished air entry at the right base and normal vesicular breathing on the left side.

Chest X-ray showed loss of volume of the right lung with consolidation of the right lower lobe. Computerized tomography (CT) scan of the patient's chest showed a thick-walled cavity in the right lower lobe with a suspected fungal ball inside the cavity (Figure 1).

Figure 1. CT Scan revealed fungal ball on right lower lobe.



On thoracotomy, the right upper lobe was normal. The right middle and right lower lobes were densely adherent to each other. They were also adherent to the parietal pleura and to the diaphragm. There was significant neovascularization of the diseased lung tissue. A thick-walled cavity with a fungal ball was present in the anterior and medial segment of the right lower lobe extending into the right middle lobe. The rest of the lung tissue formed a thick fibrous wall of the cavity. Lysis of adhesions was done. The right lower lobe and right middle lobe along with the cavity containing the fungal ball was resected and the resected tissue was sent for histopathological and microbiological examination.

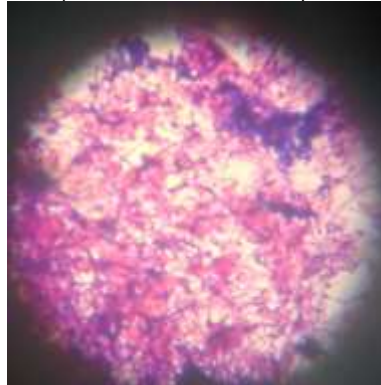
The complete blood count revealed a hemoglobin of 8 gm/dl, total leucocyte count of 9600 cells/mm³ with 80% neutrophils, 16% lymphocytes, and 4% eosinophils. The patient's peripheral blood smear revealed features of iron deficiency anemia.

A portion of specimen was inoculated on Sabouraud's dextrose agar with antibiotics, 10% sheep blood agar, and brain heart infusion broth. Sabouraud's dextrose agar was inoculated at 25°C and examined daily for up to 3 weeks. The remaining inoculated media was incubated at 37°C and examined daily for 7 days. Inoculated blood agar plates were incubated under aerobic and anaerobic conditions. The other portion of the specimen was smeared for 10% potassium hydroxide (KOH) staining, gram staining, and kinyoun's acid-fast staining.

A 10% KOH revealed very fine intertwined, narrow, delicate branching filaments. On gram staining, the organism appeared as gram-positive, beaded, coccoid, thin branching filaments (Figure 2).

Modified Ziehl-Neelsen staining (with 1% sulphuric acid) showed many branching acid-fast bacilli, consistent with the morphology of *Nocardia* species. On culture the colonies appeared as white, dry, rough, raised, folded and irregular. The isolate was further identified by standard bacteriological methods. Histopathological examination of the specimen showed delicate branching filaments of approximately 1 micrometer with a mixed cellular response of polymorphonuclear leucocytes, macrophages, and lymphocytes.

Figure 2. Photomicrograph revealed Gram-positive, filamentous, delicate branching rods with an irregular staining pattern (Gram's stain 1000X).



Postoperatively the condition of the patient rapidly deteriorated and she expired due to aspiration.

Discussion

Nocardia infection is a rare disorder caused by bacteria, which tends to affect the lung, brain, and skin. While individuals with a normal immune system can acquire this infection, the main risk factors for nocardiosis are a weakened immune system or chronic lung disease. People on chronic steroid therapy, those with cancer, organ or bone marrow transplants, or human immunodeficiency virus (HIV)/AIDS are at risk [2]. *Nocardia* are gram positive, acid fast and are stained by kinyoun's technique (modified Ziehl Neelsen technique). Weak acid-fastness of the *Nocardia* species (demonstrated by kinyoun's acid fast stain) is highly useful in differentiation from other actinomycetes such as the *Actinomyces* and *Streptomyces* species, which are also Gram-positive branching bacteria [2].

Fungal ball occurs in people who suffer a pulmonary disease which leaves a cavity in the lung, e.g. tuberculosis. In this cavity, the spores can grow into a fungal ball. In many cases, the fungal ball remains localized and asymptomatic but sometimes this fungal ball can produce invasive diseases [3]. *Aspergillus* is the commonest cause of fungal ball. *Candida*, *streptomyces*, *Pseudoallescheria boydii*, *Monosporium apiospermum*, *Conidiobolus*, *penicillium decumbens*, *Syncephalastrum species*, *Cladosporium* and *Coccidioides immitis* are the other etiological agents for fungal balls [4].

Rarely, *Nocardia* species invade preexisting lung cavities, producing a “fungal ball” appearance [5].

The cause of haemoptysis is neovascularization of the diseased segment from the internal mammary, intercostals and phrenic system of vessels. The pulmonary vascular system may also contribute to neovascularization.

Our patient was not on any immunosuppressive drug but was a malnourished female from a rural background where constant exposure to soil, grasses, weeds, cattle and polluted stagnant water is routine. These factors predisposed her to *Nocardia* infection.

Nothing in the clinical or radiographic presentation of pulmonary nocardiosis is sufficiently distinctive to be diagnostic. Clinical manifestations are variable and in no way specific.

Before the introduction of sulfonamides, mortality due to nocardiosis was 80% to 85% and surgery was the first line therapy. With the availability of effective antibiotics, medical management is now the treatment of choice. Antimicrobials such as sulphonamides, meropenem, amikacin, minocycline, cefotaxime and cefuroxime are effective against *Nocardia* species, but sulphonamides are the most comprehensively studied drugs. Optimal duration of therapy is uncertain, but long-term therapy is the rule because *Nocardia* infections tend to relapse; most recommendations are empirical. Nonimmunosuppressed patients with pulmonary or systemic nocardiosis (excluding CNS involvement) should be treated for a minimum of 6 to 12 months.

Difficulty and slowness of culture growth, along with the lack of a serologic test for nocardiosis, necessitate its inclusion in the differential

diagnosis for both immunocompromised and immunocompetent patients in whom an apparent pulmonary infection cannot be rapidly diagnosed [6].

We conclude that the *Nocardia* species is a rare cause of pulmonary fungal ball. A high index of suspicion is required to diagnose and treat nocardiosis. A timely diagnosis and appropriate treatment can reduce morbidity and mortality in such patients.

References

1. Lahiri TK, Agarwal D, Sagar Reddy GE, Bajoria Archana (2001) Pulmonary mucoraceous fungal ball. *Indian J Chest Disease Allied Science*; 43:107-110.
2. D'cruz Sanjay, Bhadada Sanjay, Chander Jagdish, Agarwal Vikas, Singh Ram, Sachdev Atul (2004) Isolated nocardial subcapsular and perinephric abscesses. *IJPM* 47(1): 24-26.
3. Gulnaz B, Suman S, Tehmeena W, Dilip KK. (2004) Pseudallescheriasis in a patient with healed tuberculosis *Mycopathologica* 158:289-291.
4. Lahiri TK, Agarwal D, Sagar Reddy GEC., Upadhyaya DN (2001) Fungal ball presentation of mucormycosis of the lung. *Antiseptic*; 98:94-96.
5. Philip LI (1996) Nocardiosis. *Clinical infectious disease*; 22:891-905.
6. Feigin DS (1986) Nocardiosis of the lung: Chest radiographic findings in 21 cases. *Radiology* 159:9-14.

Corresponding Author: Ragini Tilak, Department of Microbiology, Institute of Medical Sciences, Banaras Hindu University, Varanasi-221 005 India, Email: raginijain29@rediffmail.com

Conflict of interest: No conflict of interest is declared.